

Caplacizumab resistance in immune thrombotic thrombocytopenic purpura (TTP) mediated by VWF A1 domain missense variant

Mari Thomas^{1,2}, Sabina McCann³, Adela Constantinescu-Bercu⁴, Imogen Buckle⁴, Arshia Latif⁴, Rens De Groot⁴, Mike Mitchell⁵, Marie Scully^{1,2}

1. Department of Haematology, University College London Hospital 2. Haematology Theme, National Institute for Health Research UCLH/UCL Biomedical Research Centre 3. Haemostasis - Health Service Laboratories, London WC1H 9AX 4. Institute Cardiovascular Science, UCL 5. Molecular Haemostasis & Thrombosis, Synnovis Analytics LLP

Introduction

Caplacizumab has been shown to reduce the time to platelet normalisation, reduce TTP exacerbations and prevent refractory acute disease. We report the first case of caplacizumab ‘resistance’ in a patient with iTTP with a failure of suppression of in vivo VWF activity by the drug and persistence of VWF-mediated platelet capture in a flow-based in vitro assay.

Background

Thrombotic thrombocytopenia purpura (TTP) is a rare, life-threatening condition that is classed as a medical emergency. TTP is caused by a deficiency in ADAMTS13 metalloproteinase¹. ADAMTS13 cleaves von Willebrand factor (VWF) at Tyr1605-Met1606 within the A2 domain. The action of ADAMTS13 clears high molecular weight VWF multimers. In TTP, the deficiency of ADAMTS13 allows for the high molecular weight VWF multimers to further bind to platelets resulting in platelet rich thrombi in the microvasculature leading to organ ischemia.

The administration of caplacizumab revolutionised the treatment of TTP as it reduces the duration of thrombocytopenia, exacerbations, admission duration, number of plasma exchange (PEX) procedures and volume of plasma required². Caplacizumab is a monoclonal antibody that binds to the A1 region of VWF, and therefore inhibits platelet binding to the GPIb-IX-V receptor. As a result caplacizumab causes a significant reduction in VWF activity.

Clinical history

65 year old woman referred with two day history of petechiae and dark urine. Platelet count $7 \times 10^9/L$, mild renal impairment and raised troponin. Subsequent testing: ADAMTS13 activity $<5 IU/dL$ and ADAMTS13 antibody 76% results - confirmation of immune TTP (iTTP). Standard treatment of care commenced with PEX, administration of caplacizumab, rituximab and steroids.

14 days post diagnosis patient attended for routine rituximab infusion, however platelet count had fallen to $17 \times 10^9/L$ from $>200 \times 10^9/L$. Patient compliance confirmed for caplacizumab. Further investigations undertaken due to unusual TTP exacerbation in a patient on caplacizumab.

Materials & Methods

ADAMTS13 Activity & ADAMTS13 Antibody

ADAMTS-13 activity was measured in citrated plasma using fluorescence resonance energy transfer FRETs-VWF73 assay (NR 60 - 146 IU/dL). In-house ELISA for anti-ADAMTS13 IgG quantification (NR $<6\%$).

Microfluidic Assay

VenaFluoro8+ microchips (Cellix) were coated with collagen type 1 (Horm). Whole blood samples in lithium heparin from iTTP patients receiving caplacizumab were analysed within 4 hours of collection. Whole blood labelled with DiOC₂ (2.5μM) was perfused through channels at 1800s-1 for 3 minutes, using Mirus-Evo nanopump (Cellix). Platelet accumulation was monitored and images analysed to establish median platelet surface coverage. Surface coverage was calculated using in-house software.

Molecular Graphics

The crystal structure of the VWF A1 domain in complex with caplacizumab visualised in PyMOL. AlphaFold 3 was used to predict the structure of the mutated A1 domain with variants P1266L and V1279I (UniProt: L8E853) and alignments made in PyMOL.

Platelet Aggregation

Platelet aggregometry analysed using a PAP8E profiler with platelet rich plasma obtained from sodium citrate samples. Platelet agonists at specific concentrations: arachidonic acid (1mM), adenosine diphosphate (1, 2.5 & 5μM) collagen (1 & 4μg/ml) and ristocetin (0.5 & 1.5mg/ml). The maximum aggregation (MA) is recorded in percentage after 6 minutes of aggregation at 37°C.

Platelet Glycoprotein

Platelet glycoproteins were measured on Beckman Coulter Cytotflex.

VWF Genetic Analysis

Sanger sequencing of exon 28 of VWF gene.

VWF Activity, Antigen & Ristocetin cofactor

VWF activity (VWF:Ac) and VWF antigen (VWF:Ag) were measured in citrated plasma with automated immunoturbidimetric assay on Sysmex CS2500 analyser. Siemens VWF:Ac VWF:glycoprotein Ibm and VWF:Ag Innovance kit. VWF ristocetin was measured in citrated plasma on Sysmex CS-2100 analyzer (BC Von Willebrand reagent).

Results

Platelet count initially increased from 7 to $>200 \times 10^9/L$, but ADAMTS13 activity remained $<5 IU/dL$ (Figure 1A). Sudden drop in platelets on day 14 post diagnosis.

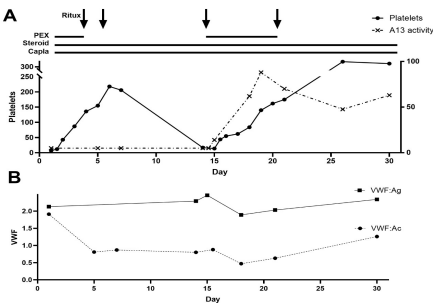


Figure 1. Longitudinal platelet count, ADAMTS13 activity and VWF activity/antigen

VWF Activity of 1.91 IU/ml prior to starting caplacizumab and lowest VWF Activity result of 0.47 IU/ml while on the monoclonal antibody (Figure 1B). The VWF activity results were unexpected, showing no suppression. VWF activity result confirmed with VWF ristocetin cofactor result 0.39 IU/ml.

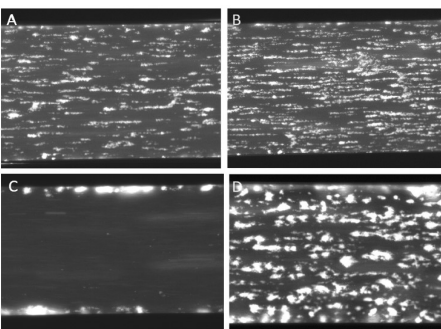


Figure 2. Microfluidic assay VWF-mediated platelet capture under flow (SC %). A. Normal control (13.2%) B. TTP patient with reduced ADAMTS13 activity not on caplacizumab showing increased platelet surface coverage (21.87%). C. iTTP patient with reduced ADAMTS14 activity on caplacizumab showing markedly reduced platelet surface coverage ($<5\%$). D. Patient (19.6%).

Increased surface coverage of 19.6% for the patient’s lithium heparin whole blood sample analysed under shear stress on collagen coated channel (Figure 2D). Other iTTP patients receiving caplacizumab analysed on the microfluidic had significantly lower surface coverage ($<5\%$) (Figure 2C).

Platelet aggregometry was normal, including absent agglutination to low dose ristocetin under standard analysis time of 6 minutes. Analysis of platelet glycoproteins by flow cytometry showed CD42b (GPIb alpha) expression of 99.98%.

Genetic analysis of exon 28 of VWF gene showed the patient to be heterozygous for two missense variants: c3797C>T, p.(Pro1266Leu) and c3835G>A, p.(Val1279Ile). The predicted structure of the P1266L/V1279I VWF A1 domain created in PyMOL (figure 3). The predicted template modelling (pTM) score of 0.94 (figure 3C), with >0.80 pTM representing confident high-quality predictions.

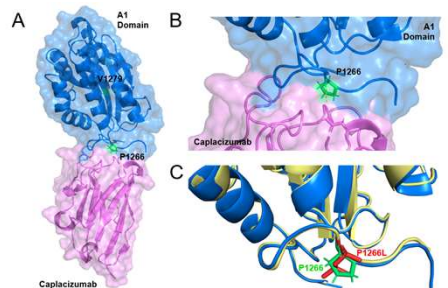


Figure 3. Crystal structure of VWF A1 Domain complexed with Caplacizumab and AlphaFold prediction of mutated VWF. A. Adapted ribbon diagram of the crystal structure of the VWF A1 domain in complex with caplacizumab. B. Polar interactions between A1 domain and caplacizumab. C. AlphaFold 3 prediction of mutated VWF A1 domain superimposed with wild type structure; P1266L mutation highlighted in red.

Conclusion

- Microfluidic flow assay supported the VWF activity result with increased platelet binding under shear stress; this method reflects in vivo physiological conditions.
- The P1266L missense variant has been reported to affect the A1-GP1b binding site³, although not in the same manner as a classical Type 2B VWD variant. The AlphaFold model (figure 3) showed interactions between the A1 domain and caplacizumab, including P1266; indicating that the mutation could affect A1 domain binding to caplacizumab.
- We report the first case of caplacizumab ‘resistance’ in a patient with iTTP with a failure of suppression of in vivo VWF activity by the drug and persistence of VWF-mediated platelet capture in a flow-based in vitro assay.
- This case study highlights that there is a requirement to investigate VWF activity levels which are not severely reduced when TTP exacerbation occurs despite daily caplacizumab therapy.

References

1. Scully, M., R. Rayment, A. Clark, J. P. Westwood, T. Cranfield, R. Gooding, C. N. Bagot et al. "A British Society for Haematology Guideline: diagnosis and management of thrombotic thrombocytopenic purpura and thrombotic microangiopathies." *British journal of haematology* 203, no. 4 (2023): 546-563.
2. Scully, M., Cataland, S.R., Peyvandi, F., Coppo, P., Knobl, P., Kremer Hovinga, J.A., Metjian, A., de la Rubia, J., Pavanski, K., Callewaert, F. and Biswas, D., 2019. Caplacizumab treatment for acquired thrombotic thrombocytopenic purpura. *New England Journal of Medicine*, 380(4), pp. 335-346.
3. Holmberg, L., Dent, J.A., Schneppenheim, R., Budd, U., Ware, J. and Ruggeri, Z.M., 1993. von Willebrand factor mutation enhancing interaction with platelets in patients with normal multimeric structure. *The Journal of clinical investigation*, 91(5), pp.2169-2177.